

Detection of Natural and Simulated Periodontal Defects Using Cone-Beam Computed Tomography and Digital Intraoral Radiography

Melis Misirli^{1*}, Secil Aksoy¹, Murat İçen², Hayriye Tumer³, Kani Bilginaylar⁴, Suzan Karaoglulari³, Atilla Berberoglu⁵, Kaan Orhan^{6,7,8}

¹Near East University, Faculty of Dentistry, Department of Dentomaxillofacial Radiology, Mersin 10, Turkey.

²Neveşehir Hacı Bektaş Veli University, Faculty of Dentistry, Department of Dentomaxillofacial Radiology, Neveşehir, Turkey.

³Final International University, Faculty of Dentistry, Department of Periodontology, Mersin 10, Turkey.

⁴Final International University, Faculty of Dentistry, Department of Oral and Maxillofacial Surgery, Mersin 10, Turkey.

⁵University of City Island, Faculty of Dentistry, Department of Periodontology, Mersin 10, Turkey.

⁶Ankara University, Faculty of Dentistry, Department of Dentomaxillofacial Radiology, Ankara, Turkey.

⁷Ankara University Medical Design Application and Research Center (MEDITAM), Ankara, Turkey.

⁸Medical University of Lublin, Department of Dental and Maxillofacial Radiodiagnostics, Lublin, Poland.

*Correspondence to: Melis Misirli (E-mail: melis.misirli@neu.edu.tr)

(Submitted: 10 December 2021 – Revised version received: 26 December 2021 – Accepted: 17 January 2022 – Published online: 26 February 2022)

Abstract

Objectives: In this study, it was aimed to compare the diagnostic value of cone beam computed tomography (CBCT) and digital intraoral periapical imaging methods in the diagnosis of periodontal defects, and the comparison of observers practicing dentistry in the field of periodontology and 3 other observers specialized in various branches was evaluated.

Methods: 7 dry mandible and 5 dry maxilla were used in this study. A total of 111 artificial and natural defects (dehiscence, furca, fenestration, vertical defects) on the anterior, premolar and molar region were imaged with digital imaging techniques using different exposure parameters and scanned with CBCT.

Results: According to the results of this study, CBCT is a more reliable method in the evaluation of all periodontal defects compared to CCD and PSP. 60 and 70 kVp with 0.01 irradiation time in CCD and 70 kVp 0.25 irradiation time in PSP is not suitable for detecting defects owing to high contrast. In the evaluation of periodontal defects, there was no single observer who had good results, different imaging methods and varying results were obtained in different defects.

Conclusion: This study showed that the CBCT method has some diagnostic value for detecting all natural and simulated periodontal defects but it should only be used in cases where clinical evaluation and conventional radiographic imaging do not provide the information necessary for an adequate diagnosis and proper periodontal treatment planning.

Keywords: Vertical defects, cone beam computed tomography, CCD, PS, exposure parameters

Introduction

Periodontal diseases are localized infections which result in inflammation of the gingiva, leading to the gradual destruction of periodontal tissues and alveolar bone supporting the teeth.¹ As a result of these periodontal diseases, various defects occur in the alveolar bone.² The absence of facial or lingual cortical plates, which results in the cervical root surface and affecting the marginal bone, represents an alveolar defect called dehiscence. Fenestration is the window-shaped alveolar bone loss in the facial or lingual surface of the tooth that directly contacts the gingival or alveolar mucosa and does not affect the marginal bone, unlike dehiscence.^{3,4} Furcation involvement is defined as the 'pathologic resorption of bone within a bi-furcation or tri-furcation areas of premolars and molars tooth.'⁵ Vertical defects are oblique defects, making an angle to the tooth root. Bone defects are classified according to the number of surviving bone walls, the width of the defect, and the topographic extent of the tooth. The number of remaining bone walls referred to here is intact and is the number of bone walls that contain regeneration-providing components. Accordingly, it is classified as a walled, two-walled and three-walled.³ When these defects are diagnosed, periodontal probes are used to evaluate gingival tissues and radiographs are used to evaluate bone support.⁶ Diagnosis of

advanced defects by using of the periodontal probe has limitations such as variables sizes and shapes of periodontal probe tips, probing force, gingival inflammation and anatomical conditions of the probing site.⁷

Radiographs are necessary for the visualization of hidden anatomical structures such as alveolar bone and to determine the extent and severity of periodontal tissues.^{8,9} They help us to determine the degree of inter radicular and interdental bone loss, length of the root, crown-root ratio, periodontal ligament space and any apical pathology in the tooth.¹ Currently, there are many intraoral and extraoral imaging methods that we can examine periodontal defects. Due to its cost, easy implementation and high resolution, generally 2D imaging methods (periapical, bitewing, panoramic) are preferred.⁷ However, there are limitations such as the superposition of anatomical structures, difficulty in establishing standardization, and examination of size and formation of bone defects. With the reason of superposition, periodontal lesions such as buccal and lingual defects and dehiscences cannot be diagnosed with intraoral radiography.^{1,8} Prediction of periodontal defects may be leading to progression of periodontal bone loss and resulting in tooth loss.¹⁰ Because of these limitations, the treatment plan is affected by the inability to fully observe periodontal defects and three dimensional (3D) examination could be considered as a superior technique.¹¹ Conventional Computed

Tomography (CT) which is revolutionized imaging solves this problem by providing multiplanar imaging of the objects. However, there are disadvantages of CT including high patient radiation dose, high cost, and low resolution.¹² The use of 3D imaging CBCT method, offers many advantages because of its lower radiation dose and less artifact compared to conventional tomography.⁸ Morphologic knowledge is crucial for treatment and prognosis in periodontology.⁹ Thus, one of the most important factors for the success of periodontal treatment is to have a true image of the morphology of periodontal bone destruction for accurate treatment planning and determination of prognosis. Several studies are available on the diagnostic accuracy of CBCT.^{8,9,11,13}

This study sought to the comparison of imaging methods to assess the diagnostic value of CBCT which is taken with different voxel and FOV sizes and digital intraoral periapical imaging methods with varying kVp and mA parameters.

Materials and Methods

In this study, 7 dry mandibles and 5 dry maxillae were used. 6 Mandibles and 4 Maxillae were used to create simulated defects, while 1 mandibula and 1 maxilla with natural defects are determined as Gold Standard and no simulated defect has been created. Artificial periodontal defects were created in the areas where natural defects were not present in all the upper and lower jaws, except the upper and lower jaws which were used as the gold standard. In total 111 artificial defects simulating dehiscence, fenestration, furca, and intrabony defects were created on the incisors, premolars and molars using a diamond-tipped burr (Jota Diamond, 4500 MAX rpm, 300000 OPT rpm) and 70–72% perchloric acid. There are 55 dehiscence defects, 14 fenestration defects, 23 furca defects, and 20 intrabony defects. The cause of the excess of dehiscence defects was the presence of natural dehiscence defects in the jaws. The pink modeling wax was placed to cover all the defects on the jaws to provide a soft tissue imitation.

The defects were prepared using high-speed equipment with hand and angle pieces and rounded burrs under copious air/water spray by a periodontal consultant (AB) at randomly selected areas. The defects were noted to be used as the 'gold standard' for radiographic evaluation. Images obtained from the defects and then to create defects induced by burr and chemical preparation, cotton pellets saturated with the 70–72% perchloric acid solution were placed on the burr-prepared cavities and then the defects examined after 12 hours later. For the first examination, the cotton pellet was removed, after examination, a new cotton pellet saturated with a fresh perchloric acid was placed on the cavities for 12 hours. Finally, the cotton pellets removed and modeling wax placed one more time for soft tissue simulation and all imaging methods repeated (Figure 1).

Digital Intraoral Imaging

After preparing all jaws, radiology researchers (MM, MI) acquired intraoral radiographs using a Sorodex Digora Optime UV (Sorodex Medical Systems, Helsinki, Finland) and Planmeca Dixi 3 CCD (Helsinki, Finland). Periapical radiographs were obtained with a parallel technique by using a film holder apparatus to provide standardization. Phosphor plate system operating at 60 and 70 kVp with three different exposure time (0.16, 0.20 and 0.25 sec) and the CCD system operating at 60

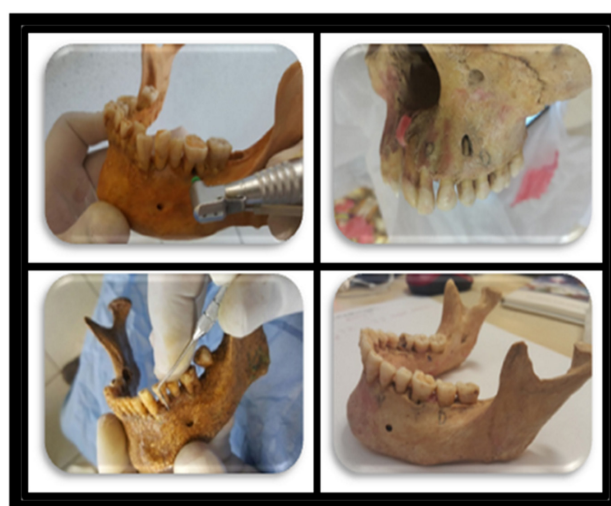

Fig. 1 The photographs of the maxilla and mandible that showing natural defect and simulated defects created with burr and chemical agent.

and 70 kVp with 0.01, 0.02, 0.03 sec exposure time. Every defect has 6 digital intraoral radiographs to compare the diagnostic quality.

Cone-beam Computed Tomography

CBCT images were obtained (Morita Veraviewepocs 3d r 100) with a flat panel detector which has 0.125 mm³ voxel, offering 2 field-of-view (FOV) sizes (8 × 8 cm and 10 × 8 cm).

Assessment of Radiographic Images

Each image set was evaluated separately by 4 different observers in random; one periodontology Ph.D. student (SK-Observer 1), one oral and maxillofacial surgeon (KB-Observer 2), one periodontologist (HT-Observer 3) with an experience of 2 years, one trained dentomaxillofacial radiologists (SA-Observer 4) with an experience of 4 years.

Observers were calibrated with the help of a powerpoint presentation of defect samples by a specialist radiologist (KO) and periodontologist (AB) on both CBCT and periapical radiography images for the diagnosis of periodontal defects. All digital intraoral images were saved in noncompressed file format (tagged image file format, TIFF). Digital intraoral images were displayed using the dedicated DICOM-Viewing software program whereas CBCT images were evaluated with its own software (Romexis 3.2, Planmeca, Helsinki, Finland). Observation conditions were optimized through use of the same computer monitor when the images were displayed. Viewing distance was kept constant to about 50 cm for the observer, and the lights were subdued during examinations. The observers were asked to identify the existence or absence of defects as well as the types of the defects (Figure 2).

The observers were unaware of the existence of the defect as well as the exposure properties of them. The final classification was; the defects were present, absent or undetectable while making the diagnosis.

Statistical Analysis

All evaluations were compared according to the identified gold standard. All statistical analyses were performed with SPSS 20.0 (SPSS*; IBM Corp., New York, NY; formerly SPSS Inc., Chicago, IL). Chi-square analysis was used to compare

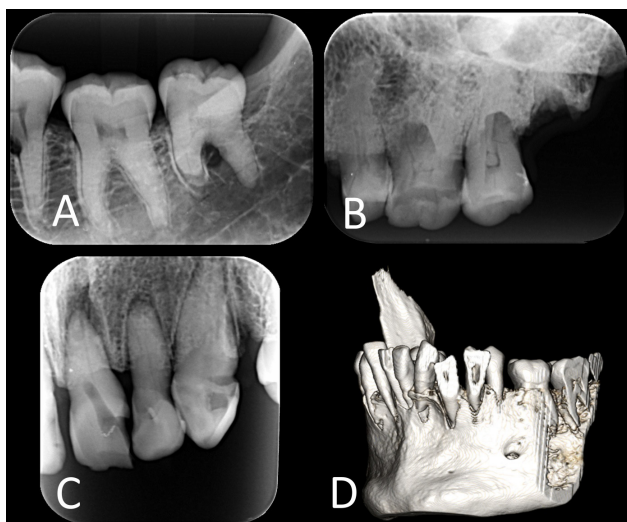


Fig. 2 2 and 3D images of the defects (A) Simulated furca defect (B) Natural dehiscence defects (C) Natural vertical defect (D) Natural dehiscence defects.

the kVp and exposure times within the CCD and phosphor plate system. Kappa statistics were used for assessing the agreement between observers. The kappa values were interpreted according to guidelines of Landis and Koch adapted by Altman: $k \leq 0.20$ poor, 0.21–0.40 fair, 0.41–0.60 moderate, 0.61–0.80 good, 0.81–1.00 very good. The determination of significance level was carried out with the *t*-test using paired samples. Results were considered significant at $P < 0.05$.

Results

Table 1 displays the diagnostic sensitivity, kappa coefficients, and *P*-value, calculated for each observer of CCD, phosphor plate system and CBCT according to for vertical defects (1, 2 and 3 wall intrabony defects). The results revealed that 60 kVp exposure time of 0.01 second was not suitable for all observers

for detection of the defects. The first observer who is an inexperienced periodontology research assistant could not diagnose any vertical defects from the radiographs, which are taken by CCD although all other observers can identify it. The diagnostic sensitivity of CCD and PSP are similar however, CBCT sensitivity was significantly higher than digital radiography techniques for the detection of vertical defects.

Table 2 shows that the sensitivity of CCD and PSP for the detection of dehiscence defects. CBCT images again (10×8, 8×8) are superior ($P < 0.05$) to detect dehiscence defects then conventional radiographies ($P > 0.05$) for all observers. Only 4th observer (radiologist) diagnosed all dehiscence defects from the CCD and phosphor plate system except the 60 and 70 kVp exposure time of 0.01 second.

The results also showed that CCD and PSP can diagnose furca defects ($P < 0.05$) rather than dehiscence defects but the sensitivity values of CBCT were higher than those of digital radiography (Tables 2 and 3).

Table 4 shows the *P*-value ($P < 0.05$) of all modalities are equal when detecting fenestration defects. CBCT showed statistically better diagnostic quality and performance on detecting all defects except the fenestration defects ($P < 0.05$).

Discussion

The results of this study have generally shown that CBCT is superior to digital periapical radiography in diagnosing all types of periodontal defects with the same other studies.^{1,8,9,13,14}

Fenestrations are isolated areas in which the exposed root surface is covered only by the periosteum and gingiva, but marginal bone is unaffected. When this erosion extends to the marginal bone, it is called dehiscence. Radiologic examination of advanced periodontal defects involving fenestration and dehiscence is essential.¹⁵ These defects cannot be visualized by traditional two-dimensional radiography because of the superposition of contralateral cortical bony or dental structures. Three-dimensional radiography techniques can be

Table 1. Intra-observer agreement calculated for each observer by image type for vertical defects

	Vertical defects											
	Observer 1			Observer 2			Observer 3			Observer 4		
	Sensitivity	Kappa	<i>P</i>	Sensitivity	Kappa	<i>P</i>	Sensitivity	Kappa	<i>P</i>	Sensitivity	Kappa	<i>P</i>
60 kVp 0.01	60	0,062	0,369	40	0,121	0,172	42.11	0,175	0,055	57.89	0,147	0,068
60 kVp 0.02	60	0,112	0,134	45	0,148	0,09	55	0,243	0,006*	50	0,185	0,034*
60 kVp 0.03	60	0,12	0,112	50	0,219	0,014*	50	0,174	0,044*	55	0,188	0,026*
70 kVp 0.01	60	0,056	0,416	50	0,213	0,018*	47.37	0,216	0,018*	55	0,14	0,084
70 kVp 0.02	65	0,118	0,1	60	0,278	0,001*	55	0,17	0,055	60	0,254	0,003*
70 kVp 0.03	70	0,109	0,103	60	0,266	0,002*	50	0,243	0,007*	60	0,171	0,032*
60 kVp 0.16	45	-0,029	0,684	45	0,272	0,003*	45	0,205	0,023*	60	0,21	0,011*
60 kVp 0.20	65	0,184	0,018*	45	0,258	0,005*	35	0,124	0,173	40	0,11	0,208
60 kVp 0.25	65	0,161	0,036*	42.11	0,156	0,082	30	0,071	0,434	60	0,241	0,005*
70 kVp 0.16	50	0,038	0,609	40	0,165	0,068	40	0,259	0,005*	45	0,148	0,09
70 kVp 0.20	60	0,208	0,015*	47.37	0,316	0,001*	50	0,281	0,002*	45	0,207	0,027*
70 kVp 0.25	68.75	0,147	0,079	44.44	0,135	0,184	44.44	0,2	0,052	63.16	0,276	0,003*
CBCT 10x8	70	0,146	0,04*	70	0,429	0,001*	65	0,41	0,001*	75	0,115	0,072
CBCT 8x8	70	0,146	0,04*	70	0,429	0,001*	65	0,41	0,001*	75	0,115	0,072

Table 2. Intra-observer agreement calculated for each observer by image type for dehiscences

	Dehiscence											
	Observer 1			Observer 2			Observer 3			Observer 4		
	Sensitivity	Kappa	P	Sensitivity	Kappa	P	Sensitivity	Kappa	P	Sensitivity	Kappa	P
60 kVp 0.01	7.27	0,025	0,595	10.91	0,007	0,879	7.27	0,025	0,595	16.36	0,068	0,295
60 kVp 0.02	5.45	0,023	0,564	10.91	0,045	0,404	7.27	0,025	0,595	25.45	0,195	0,005*
60 kVp 0.03	5.45	0,04	0,261	7.27	0,028	0,619	7.27	0,025	0,595	29.09	0,233	0,001*
70 kVp 0.01	5.45	0,023	0,564	10.91	-0,01	0,853	9.09	0,044	0,376	20	0,122	0,066
70 kVp 0.02	5.45	0,04	0,261	10.91	0,045	0,404	12.73	0,081	0,135	29.09	0,25	0,001*
70 kVp 0.03	7.27	-0,012	0,803	7.27	0,062	0,228	10.91	0,045	0,404	18.18	0,138	0,024*
60 kVp 0.16	7.27	0,042	0,332	14.55	0,066	0,279	5.45	-0,03	0,561	23.64	0,143	0,045*
60 kVp 0.20	1.82	-0,015	0,621	10.91	0,011	0,85	3.64	-0,05	0,303	23.64	0,16	0,022*
60 kVp 0.25	1.82	-0,015	0,621	16.36	0,085	0,178	7.27	0,025	0,595	30.91	0,268	0,001*
70 kVp 0.16	7.27	0,042	0,332	14.55	0,015	0,823	3.64	-0,01	0,734	27.27	0,213	0,001*
70 kVp 0.20	5.45	0,006	0,896	20	0,122	0,066	3.64	0,004	0,916	27.27	0,231	0,001*
70 kVp 0.25	5.45	0,023	0,564	9.09	0,044	0,376	3.64	0,021	0,499	21.82	0,192	0,002*
CBCT 10x8	60	0,223	0,016*	61.82	0,324	0,001*	60	0,306	0,001*	60	0,223	0,016*
CBCT 8x8	60	0,223	0,016*	61.82	0,324	0,001*	60	0,306	0,001*	60	0,223	0,016*

Table 3. Intra-observer agreement calculated for each observer by image type for furca defects

	Furca defects											
	Observer 1			Observer 2			Observer 3			Observer 4		
	Sensitivity	Kappa	P	Sensitivity	Kappa	P	Sensitivity	Kappa	P	Sensitivity	Kappa	P
60 kVp 0.01	56.52	0,676	0,001*	65.22	0,724	0,001*	78.26	0,852	0,001*	43.48	0,552	0,001*
60 kVp 0.02	56.52	0,676	0,001*	73.91	0,793	0,001*	78.26	0,852	0,001*	43.48	0,552	0,001*
60 kVp 0.03	60.87	0,714	0,001*	73.91	0,82	0,001*	78.26	0,852	0,001*	47.83	0,595	0,001*
70 kVp 0.01	56.52	0,676	0,001*	73.91	0,82	0,001*	78.26	0,852	0,001*	47.83	0,636	0,001*
70 kVp 0.02	60.87	0,714	0,001*	73.91	0,82	0,001*	78.26	0,852	0,001*	47.83	0,595	0,001*
70 kVp 0.03	60.87	0,714	0,001*	73.91	0,793	0,001*	78.26	0,852	0,001*	43.48	0,552	0,001*
60 kVp 0.16	47.83	0,595	0,001*	65.22	0,724	0,001*	69.57	0,786	0,001*	56.52	0,676	0,001*
60 kVp 0.20	47.83	0,595	0,001*	78.26	0,826	0,001*	65.22	0,75	0,001*	56.52	0,676	0,001*
60 kVp 0.25	47.83	0,636	0,001*	73.91	0,793	0,001*	69.57	0,786	0,001*	56.52	0,676	0,001*
70 kVp 0.16	47.83	0,595	0,001*	73.91	0,793	0,001*	69.57	0,786	0,001*	60.87	0,714	0,001*
70 kVp 0.20	39.13	0,508	0,001*	73.91	0,793	0,001*	65.22	0,75	0,001*	60.87	0,714	0,001*
70 kVp 0.25	47.83	0,595	0,001*	69.57	0,734	0,001*	69.57	0,786	0,001*	60.87	0,714	0,001*
CBCT 10x8	82.61	0,807	0,001*	82.61	0,832	0,001*	78.26	0,8	0,001*	82.61	0,807	0,001*
CBCT 8x8	82.61	0,807	0,001*	82.61	0,832	0,001*	78.26	0,8	0,001*	82.61	0,807	0,001*

useful when diagnosing present fenestration or dehiscences.^{16,17} Early correct diagnosis plays an important role in the diagnosis and treatment of primary stages of periodontal defects.⁷ Noujeim et al. reported that the difference between CBCT and periapical radiography in diagnosing small defects was greater than the determination of large defects and therefore emphasized the importance of CBCT in the detection of early lesions.¹

The periapical images obtained in this study using 60 kVp, 8 mA and 0.16 s and CBCT (Morita, 3DX Accuitomo) images obtained by using 0.125 mm³ voxel sizes were compared in terms of diagnosis of simulated furca defects. It has been

shown that CBCT has higher diagnostic accuracy (periapical radiography = 0.783, KIBT = 0.864). In this study, similar to previous study CBCT had higher diagnostic accuracy (CCD and PSP = 0.782, KIBT = 0.82) similar to Noujeim et al.¹

Misch et al.⁶ compared periapical radiographs with CBCT and periodontal probing with electronic calipers in measuring the depth of buccal, lingual, and interproximal periodontal defects that they created with a bur on two dry human mandibles. They stated that, periodontal probing was more advantageous than electronic calipers, however, there was no significant difference between periapical radiographs and

Table 4. Intra-observer agreement calculated for each observer by image type for fenestration defects

	Fenestration											
	Observer 1			Observer 2			Observer 3			Observer 4		
	Sensitivity	Kappa	P	Sensitivity	Kappa	P	Sensitivity	Kappa	P	Sensitivity	Kappa	P
60 kVp 0.01	14,29	0,324	0,001*	28,57	0,382	0,001*	21,43	0,296	0,001*	28,57	0,413	0,001*
60 kVp 0.02	21,43	0,324	0,001*	35,71	0,461	0,001*	28,57	0,382	0,001*	28,57	0,413	0,001*
60 kVp 0.03	21,43	0,324	0,001*	28,57	0,382	0,001*	21,43	0,296	0,001*	28,57	0,413	0,001*
70 kVp 0.01	28,57	0,413	0,001*	35,71	0,461	0,001*	21,43	0,296	0,001*	28,57	0,413	0,001*
70 kVp 0.02	28,57	0,413	0,001*	35,71	0,461	0,001*	21,43	0,296	0,001*	28,57	0,413	0,001*
70 kVp 0.03	28,57	0,413	0,001*	28,57	0,382	0,001*	21,43	0,296	0,001*	28,57	0,413	0,001*
60 kVp 0.16	21,43	0,324	0,001*	42,86	0,569	0,001*	35,71	0,461	0,001*	35,71	0,494	0,001*
60 kVp 0.20	21,43	0,324	0,001*	50	0,638	0,001*	28,57	0,327	0,001*	35,71	0,461	0,001*
60 kVp 0.25	21,43	0,324	0,001*	50	0,638	0,001*	28,57	0,327	0,001*	35,71	0,494	0,001*
70 kVp 0.16	21,43	0,324	0,001*	42,86	0,569	0,001*	35,71	0,43	0,001*	35,71	0,494	0,001*
70 kVp 0.20	21,43	0,324	0,001*	35,71	0,494	0,001*	28,57	0,413	0,001*	35,71	0,494	0,001*
70 kVp 0.25	21,43	0,324	0,001*	21,43	0,324	0,001*	28,57	0,413	0,001*	28,57	0,413	0,001*
CBCT 10x8	50	0,568	0,001*	42,86	0,502	0,001*	42,86	0,502	0,001*	57,14	0,629	0,001*
CBCT 8x8	50	0,568	0,001*	42,86	0,502	0,001*	42,86	0,502	0,001*	57,14	0,629	0,001*

CBCT. In a similar study, Langen et al.¹⁸ compared conventional radiographs and CT for the diagnosis of 55 vertical defects. It was reported that only 38 of 55 defects (69.1%) can be detected by conventional radiographs and 100% defects could be detected on CT images. In another study Mengel et al.¹⁹ reported that intraoral radiographs were inadequate in buccolingual examinations and that image quality was better in CBCT, consistent with the results of the study. The results of this study showed only 14 of 20 simulated vertical defects can be detected by CCD images (70%), 13 defects by PSP (65%) and 16 (80%) with CBCT among all observers.

Sun et al.²⁰ reported that 83% (sensitivity = 0.83) of the actual dehiscence defects and 73% (specificity = 0.73) of the non-defects areas, 71% (sensitivity = 0.71) of the actual fenestration defects and 77% (specificity = 0.77) of the non-defect areas were correctly diagnosed at the end of the study. They reported that there is a high probability of prediction with CBCT when the opening angle in dehiscence is more than 3 mm. The results of this study were comparable with previous studies Noujeim et al.¹ Sun et al.²⁰ 64% (sensitivity = 0.64) of the actual fenestration defects, 73% (sensitivity = 0.73) of the actual dehiscence defects and 82% (sensitivity = 0.82) of the actual furca defects were correctly diagnosed.

Our study was also compared with CCD and PSP radiography techniques. It has been shown that CCD and PSP are similar in the diagnosis of furca defects, but dehiscence and fenestration defects are diagnosed better with PSP. Vanderberghe et al.¹³ stated in their study that there was no significant difference between the two methods of determining the bone level in the study, however 29-41% the crater and furca defects were diagnoses wrong by PSP and, in contrast 71% of the crater defects and 56% of the furca defects could be diagnosed by CCD. In the meantime CBCT images diagnosed 100% of both crater and furca defects. Similar to these results in this study 29% of dehiscence defects, approximately 42% of fenestration defects and 78.26% of furca defects could be

diagnosed correctly using CCD, also 32.73% of dehiscence defects, 50% of fenestration defects and 78.26% of furca defects could be visualized by PSP.

In a similar study, Kolsuz et al.⁸ create 35 artificial defects (dehiscence, fenestration, tunnel) on 12 dry skulls to compare different FOV and voxel sizes (4x4 FOV-0.080 mm³, 6x6 FOV-0.125 mm³, 8x8 FOV-0.160 mm³, 5x5.5 FOV-0.100 mm³, 5x5.5 FOV-0.150 mm³, 10x5.5 FOV-0.200 mm³, 4x4 FOV-0.080 mm³ and 6x6 FOV-0.125 mm³) when detecting periodontal defects. They reported that the best voxel size for the diagnosis of periodontal defects is 0.150 mm³. In this study, we tested different FOV sizes (10x8, 8x8) under 0.125 mm³ constant voxel size to compare to assess whether there was a difference in the diagnosis of periodontal defects. Different FOV sizes did not cause a resolution change that could affect the diagnosis of the defect. Similar to this study Salineiro et al.⁵ compared two different voxel sizes with fixed FOV value of CBCT machine (ProMax 3D Max, Planmeca Helsinki, Finland, 5x5.5 FOV, 0.2 and 0.15 mm³ voxel size) with periapical radiographs to detect the incipient furcation involvement. They concluded that both CBCT imaging protocols showed higher accuracy, sensitivity, and specificity than periapical radiographs in the detection of incipient furcation involvement, even in the presence of a metallic post. Aljehani¹² analyzed 3 different voxel sizes for the assessment of periodontal furcation involvement. The authors concluded that larger voxel size reduced the accuracy of the assessment of periodontal furcation involvement, but not to a significant extent. In this study, there was no significant difference for detecting periodontal defects in different FOV values.

In a CBCT study by Umetsubo et al.²¹ the sensitivity and specificity values of CBCT (0.2 mm³ voxel value, FOV: 6x16) was examined in the diagnosis of early furca defects. They created artificial furca defects on molar teeth of pig mandibles using 70% perchloric acid and scanned with 0.2 mm voxel size and 6x16 cm FOV CBCT. They found that the sensitivity values ranging from 50% to 75% and specificity values ranging

from 93% to 100% were detected in the diagnosis of furca defects.

In this study artificial defects were created mechanically by burrs, radiographs were obtained and radiographs were repeated with 70% perchloric acid on the defects. The sensitivity of the best observer for the furca defects is 82.61% and the specificity values are 97.85% for the mechanically opened defects. For the defects formed by using mechanical + acid, the sensitivity value is 86.96% and the specificity value is 94.62%. This difference can be due to the different voxel size of the CBCT. In addition to this, Pinheiro et al.²² indicated in their study that small lesions were detected more effectively using CBCT than PSP, and larger lesions were detected more effectively by CBCT at 90 kVp than by CBCT at 75 kVp or by PSP. Similar to previous studies Leung et al.,²³ and Bayat et al.,⁷ showed that CBCT superior to PSP in the diagnosis of all of furca, dehiscence, fenestration and vertical defects.

There are some limitations of this study; since our defects did not open on a millimeter basis, it was not possible to determine which imaging method is better for detecting small or large defects. Moreover, the use of various FOV values and different voxel sizes may change the results positively, and more detailed studies are required for this purpose.

In conclusion, CBCT is a more reliable method in evaluating all periodontal defects than CCD and PSP. The 0.125 mm³ voxel size used in the study is suitable for the determination of periodontal defects, but the different FOV values are not found to be positively related to the diagnosis. Although CBCT has the advantage of being 3D but it's not suitable to use as a first imaging method to detect periodontal lesions due to high radiation doses relative to intraoral radiographs. For this reason, CBCT should be preferred in cases where complex periodontal lesions and defects are present.

Ethical Approval

All procedures performed in studies involving human participants were in accordance with the ethical standards of the institutional and/or national research committee and with the 1964 Helsinki Declaration and its later amendments or comparable ethical standards. Informed consent was obtained from all patients or their legal delegates. The study was approved by the Local Ethic Committee of the Faculty of Medicine (No. YDU/2015/33-232).

Conflict of Interest

The authors declare no conflicts of interest. ■

References

- Noujeim M, Prihoda TJ, Langlais R, Nummikoski P, (2009). Evaluation of high-resolution cone-beam computed tomography in the detection of simulated inter radicular bone lesions. *Dentomaxillofac. Radiol.* 38:156–162.
- Larato DC, (1970). Periodontal Bone Defects in the Juvenile Skull. *J. Periodontol* 41:473–475.
- Newman MG, Takei HH, Klokkevold PR, Carranza FA, (2012). Carranza's Clinical Periodontology, 11th edn; Saunders, Louis, Missouri.
- Enhos S, Uysal T, Yağcı A, Veli İ, Uçar FI, Ozer T, (2012). Dehiscence and fenestration in patients with different vertical growth patterns assessed with cone-beam computed tomography. *Angle Orthod.* 82:868–874.
- Salineiro FCS, Gialain IO, Kobayashi-Velasco S, Pannuti CM, Cavalcanti MGP, (2017). Detection of furcation involvement using periapical radiography and 2 cone-beam computed tomography imaging protocols with and without a metallic post: An animal study. *Imaging Sci. Dent.* 47:17–24.
- Misch KA, Yi ES, Sarment DP, (2006). Accuracy of cone-beam computed tomography for periodontal defect measurements. *J. Periodontol.* 77:1261–1266.
- Bayat S, Talaeipour AR, Sarlati F, (2016). Detection of simulated periodontal defects using cone-beam CT and digital intraoral radiography. *Dentomaxillofac. Radiol.* 45:20160030.
- Kolsuz ME, Bagis N, Orhan K, Avsever H, Demiralp KÖ, (2015). Comparison of the influence of FOV sizes and different voxel resolutions for the assessment of periodontal defects. *Dentomaxillofac. Radiol.* 44:10250070.
- Bagis N, Kolsuz ME, Kursun S, Orhan K, (2015). Comparison of intraoral radiography and cone-beam computed tomography for the detection of periodontal defects: an in vitro study. *BMC Oral Health.* 28:64.
- Meyer MS, Joshipura K, Giovannucci E, Michaud DS, (2008). A review of the relationship between tooth loss, periodontal diseases, and cancer. *Cancer Causes Control.* 19:895–907.
- Vanderberghe B, Jacobs R, Yang J, (2008). Detection of periodontal bone loss using digital intraoral and cone-beam computed tomography images: an in vitro assessment of bony and/or infrabony defects. *Dentomaxillofac. Radiol.* 37:252–260.
- Aljehani YA, (2014). Diagnostic applications of cone-beam CT for periodontal diseases. *Int. J. Dent.* 2014:865079.
- Vanderberghe B, Jacobs R, Yang J, (2007). Diagnostic validity (or acuity) of 2D CCD versus 3D CBCT-images for assessing periodontal breakdown. *Oral Surg. Oral Med. Oral Pathol. Oral Radiol.* 104:395–401.
- Mol A, (2000). Imaging Methods in Periodontology. *Periodontol* 2000. 34:34–48.
- Chiapasco M, Zaniboni M, (2009). Clinical outcomes of GBR procedures to correct peri-implant dehiscences and fenestrations: a systematic review. *Clin. Oral Implants Res.* 20:113–123.
- Timock AM, Cook V, McDonald T, Leo MC, Crowe J, Benninger BL, Jr Covell DA, (2011). Accuracy and reliability of buccal bone height and thickness measurements from cone-beam computed tomography imaging. *Am. J. Orthod. Dentofacial Orthop.* 140:734–744.
- Sun Z, Smith T, Kortam S, Kim DG, Tee BC, Fields H, (2011). Effects of bone thickness on alveolar bone-height measurements from cone beam computed tomography images. *Am. J. Orthod. Dentofacial Orthop.* 139:117–127.
- Langen HJ, Fuhrmann R, Diedrich P, Günther RW, (1995). Diagnosis of infra-alveolar bony lesions in the dentate alveolar process with high-resolution computed tomography. *Invest. Radiol.* 30:421–426.
- Mengel R, Candir M, Shiratori K, Flores-de-Jacoby L, (2005). Digital volume tomography in the diagnosis of periodontal defects: An in vitro study on native pig and human mandibles. *J. Periodontol.* 76:665–673.
- Sun L, Zhang L, Shen G, Wang B, Fang B, (2015). Accuracy of cone-beam computed tomography in detecting alveolar bone dehiscences and fenestrations. *Am. J. Orthod. Dentofacial Orthop.* 147:313–323.
- Umetsubo OS, Gaia BF, Costa FF, Cavalcanti MG, (2012). Detection of simulated incipient furcation involvement by CBCT: an in vitro study using pig mandibles. *Braz. Oral Res.* 26:341–347.
- Pinheiro LR, Scarfe WC, de Oliveira Sales MA, Gaia BF, Cortes ARG, Cavalcanti MGP, (2017). Effectiveness of Periapical Radiography Versus Cone Beam Computed Tomography with Different Kilovoltage Settings in the Detection of Chemically Created Peri-implant Bone Defects: An In Vitro Study. *Int. J. Oral Maxillofac. Implants.* 32:741–750.
- Leung CC, Palamo L, Griffith R, Hans MG, (2010). Accuracy and reliability of cone-beam computed tomography for measuring alveolar bone height and detecting bony dehiscences and fenestrations. *Am. J. Orthod. Dentofacial Orthop.* 137:109–119.

This work is licensed under a Creative Commons Attribution-NonCommercial 3.0 Unported License which allows users to read, copy, distribute and make derivative works for non-commercial purposes from the material, as long as the author of the original work is cited properly.