

Anatomical relationship of optic nerve canal to the posterior paranasal sinuses on computerized tomography in Iraqi patients

Haider Najim Al-Tameemi^a and Haider Abdul Kadum Hassan^b

^aDepartment of Radiology, College of Medicine, University of Kufa, Najaf, Iraq.

^bDepartment of Radiology, Al-Sadder Medical City, Najaf, Iraq.

Correspondence to Haider Najim Al-Tameemi (email: haidern.altameemi@uokufa.edu.iq).

(Submitted: 14 March 2018 – Revised version received: 19 May 2018 – Accepted: 12 June 2018 – Published online: 26 September 2018)

Objective To determine the patterns of relationship between optic nerve canal and posterior paranasal sinuses (PNS) in Iraqi patients from Middle Euphrates region using computerized tomography (CT).

Methods A cross-sectional observational study was conducted on 100 patients (52 male, 48 female) referred to the CT unit for evaluation of PNS. Patients were examined by the same CT device without intravenous contrast medium. Patients with sphenoid/ethmoid tumors, trauma or history of surgical intervention and those less than 13 years old were excluded. The relationship between optic canal and posterior PNS was evaluated using criteria of Delano's classification. Pneumatization of the anterior and posterior clinoid processes (PACP and PPCP) and any bony dehiscence in the bony wall were observed.

Results The most frequent type of optic canal according to Delano's classification was type I (77.5). There was no statistically significant age or gender difference. There was statistically significant higher frequency of dehiscence in higher Delano's types III (4 of 7 cases, 57.1%) and IV (6 of 8, 75%). PACP and PPCP showed statistically significant association with type IV and to lesser extent in type III. All cases of PPCP were seen only in types III and IV with statistically significant difference.

Conclusion The relationship between optic nerve and sphenoid sinuses was slightly different in our patients from other populations. Therefore, Iraqi radiologists and Ear–Nose–Throat surgeons need to be aware of this anatomical difference to avoid serious damage to the optic nerve. During pre-operative CT assessment, it is important for radiologist to pay attention to the presence of optic canal bony dehiscence in higher Delano's types. Presence of PACP and PPCP may alert to the presence of higher Delano's types, hence a serious optic nerve canal course.

Keywords paranasal sinus, computerized tomography, optic nerve

Introduction

Anatomically, the sphenoid sinuses are located at the skull base at the junction of the anterior and middle cerebral fossae. The lateral wall of the sphenoid sinus can show various prominences, the most important being the carotid canal and the optic canal. The optic canal is found in the posterosuperior angle between the lateral, posterior and superior walls of the sinus. Pneumatization of the sphenoid above and below the optic canal can result, respectively, in a supraoptic recess and an infraoptic recess.^{1,2} In some cases, dehiscence in the bony margin can also be present.³

Ethmoid sinus consists of multiple obliquely oriented parallel groups of air cells between the lateral nasal wall and the medial orbital wall.^{4,5} The sphenothmoid cells, or Onodi cells, are important group of ethmoid cells, where the posterior ethmoid cells extend superiorly or laterally to the sphenoid sinus, and the pneumatization can reach the clinoid processes, and become closely related to the optic nerve. Therefore, accurate identification of these structures and possibly Onodi cells on a preoperative computerized tomography (CT) scan is the best way to avoid such severe complications.⁶

Functional endoscopic sinus surgery (FESS) is a minimally invasive and effective surgical technique⁷ for treating chronic inflammatory sinus disease. Moreover, during last two decades and with the significant technical improvement in surgical and diagnostic tools, FESS has also become one of the treatments of choice in the orbital and skull base problems.^{8,9} However, FESS is not totally safe as many complications have been reported¹⁰ with blindness secondary to the optic nerve

damage being one of the most catastrophic ones.¹¹ Therefore, for the FESS to be successful and to minimize complications, it is mandatory to clearly understand and accurately depict the sinonasal anatomy. This depiction is routinely done in a plane corresponding to the surgical orientation and is elegantly accomplished by the CT scan, which has been established as the imaging technique of choice for demonstration of the sinonasal anatomy before FESS.¹²

Considering the documented ethnic variations in sinonasal anatomy,¹³ this study was conducted to assess the patterns of the relationship between optic nerve canal and posterior paranasal sinuses in Iraqi patients so that Iraqi radiologists and Ear–Nose–Throat (ENT) surgeons will have an idea about regional anatomical variations regarding this critical relationship. The study assumes to include a sample that represents Iraqi population from the Middle Euphrates territory because patients visiting our CT unit are not only from Najaf governorate's cities, but also from nearby governorates. Up to our best knowledge and search, there is no published article specifically assessing the patterns of the optic nerve canal in relation to posterior paranasal sinuses (PNS) in Iraqi population.

Materials and Methods

This hospital-based cross-sectional observational study was conducted on 100 patients (52 male, 48 female) in the CT unit of Middle Euphrates Neurocenter, Al-Sadder Medical City, Najaf, Iraq.

Inclusion criteria

All patients referred from ENT specialist for evaluation of sinonasal diseases and were examined by CT scan using paranasal sinuses protocol.

Exclusion criteria

Patients with known or obvious sphenoid/ethmoid tumor, trauma or history of surgical intervention were excluded. Children less than 13 years old (when the sphenoid sinus is not yet well developed) were also excluded.

Data acquisition

Relevant demographic and clinical data were taken. The radiological, coronal, axial and sagittal CT sections of the PNS for each patient were evaluated by a board-certified radiologist in the following approach:

1. General evaluation to assess for any exclusion criteria.
2. Specific evaluation of the relationship between optic nerve and sphenoid and ethmoid sinuses on both right and left sides using criteria of 4-grades Delano's system,¹⁴ which classifies the course of the optic nerve canal into: type I, adjacent to sphenoid sinus; type II, indentation on sphenoid sinus; type III, optic nerve traversing sphenoid sinus; and type IV, adjacent to sphenoid and posterior ethmoid sinuses.
3. Further evaluation of any other significant variation in the sphenoid sinus that can affect the optic nerve (like pneumatization of the anterior and posterior clinoid processes) as well as any bony dehiscence.

Statistical analysis of the data was done using SPSS, version 2.0. Sample size was calculated by the standard equation of sample size for cross-sectional study with confidence level of 95%. $N = Z \times P(1 - P) \div D$, where: N = sample size; $Z = 1.96$ for confidence 95%; P = prevalence of variation (for grade 3 which is the rarest type) which equal to 0.007 (7%); $D = 0.005$ allowed error (chance error). $N = (1.96) \times 0.07(1 - 0.07) \div (0.05) = 99.9$. Hundred patients were included in this study (corresponding to 200 optic nerves). The frequency of each of Delano's type was calculated. The correlation of different Delano's types with the pneumatization of anterior and posterior clinoid processes and with bony dehiscence was assessed using Pearson correlation coefficient. P -value of <0.05 was considered as statistically significant.

No patient consent was obtained because of the non-interventional nature of the study, with the confidentiality of patient's personal data being preserved.

Results

This study included 100 patients (48 female and 52 male) with mean age of 33.94 ± 12.39 years. Collectively, a total of 200 optic nerve canals were studied. Generally, all Delano's types were more frequent in young age groups (15–35 years). However, this predominance was not statistically significant (P values were 0.780 for the right side and 0.694 for the left side).

Types of optic nerve canals according to Delano's classification

The most frequent type of optic nerve canal according to Delano's classification (Figs. 1–4) was type I (77.5%), followed by type II (15%), type IV (4%) and least type III (3.5%) with almost approximate right to left prevalence (Table 1).

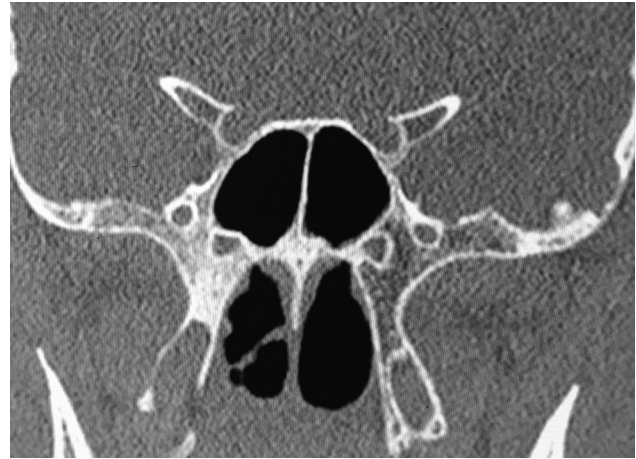

Fig. 1 Coronal CT image of a 44-year-old male showing type I Delano's classification of optic nerve relation to the sphenoid sinus.

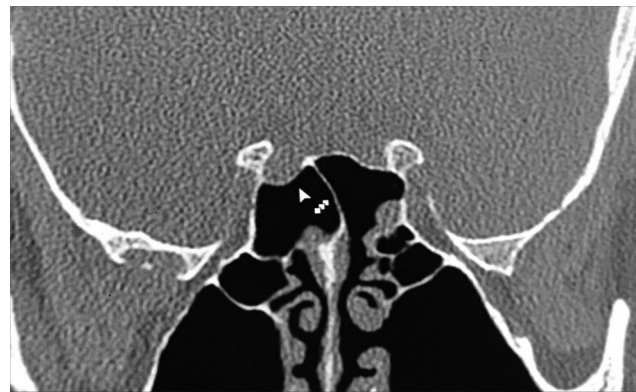

Fig. 2 Coronal CT image of a 50-year-old male showing type II Delano's classification of optic nerve relation to the sphenoid sinus.

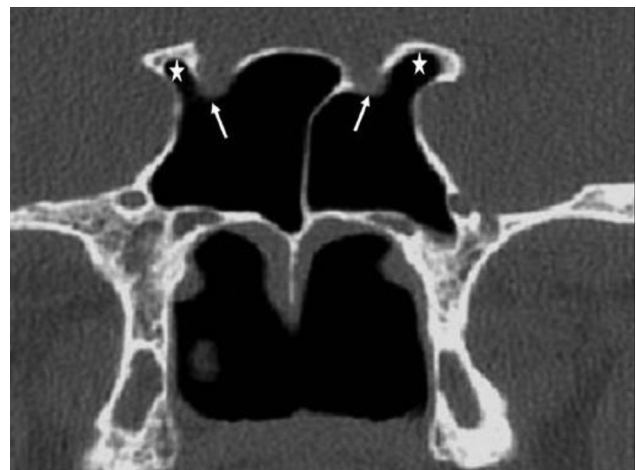


Fig. 3 Coronal CT image of a 45-year-old female showing type III Delano's classification of optic.

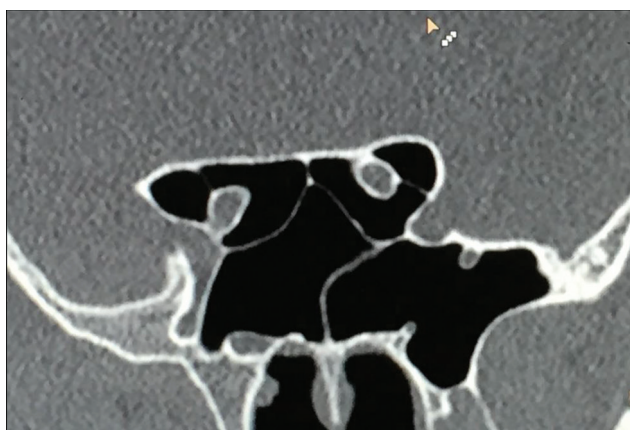


Fig. 4 Coronal CT image of a 25-year-old male showing type IV Delano's classification of optic nerve relation to the sphenoid sinus.

Table 1. Frequency of the optic nerve canal according to Delano's classification

Type	Right	Left	Total	P-value
I	79*(79%)	76 (76%)	155 (77.5%)	
II	13 (13%)	17 (17%)	30 (15%)	
III	4 (4%)	3 (3%)	7 (3.5%)	0.929
IV	4 (4%)	4 (4%)	8 (4%)	
Total	100 (100%)	100 (100%)	200 (100%)	

*Values between brackets are percentages.

Relation between Delano's and gender

There was a male predominance in type I on both sides and type II only on right. Female predominance was present in type III on both sides and only in left in type II. Type IV was equally seen in both genders and on both side. However, no type showed statistically significant difference with all *P*-value of <0.005 (Table 2).

Relationship between Delano's types and optic nerve canal dehiscence

There was a statistically significant high frequency of dehiscence in higher Delano's types III (4 of 7 cases, 57.1%) and IV (6 of 8, 75%) as demonstrated in Table 3, Fig. 5.

Delano's types and pneumatization of the anterior clinoid process

Among the 200 optic nerve canals studied, 22 were associated with pneumatization of the anterior clinoid processes (PACP), however, was only statistically significant in type IV (5 out of 8, 62%, *P*-value 0.001) and to lesser extent in type III (2 out of 7, 28.5%, *P*-value 0.04) as shown in Table 4, Fig. 6.

Delano's types and pneumatization of the posterior clinoid process

All four cases of pneumatization of the posterior clinoid processes (PPCP) seen in our study were present only in types III (2 out of 6, 28.5%) and IV (2 out of 8, 25%) with statistically significant difference. No PPCP was seen in either type I or type II (Table 5).

Table 2. Relationship between gender and Delano's types of optic nerve canal

Type	Side	Male	Female	P-value
I	Right	41	38	0.559
	Left	43	33	
II	Right	8	5	0.153
	Left	6	11	
III	Right	1	3	0.809
	Left	1	2	
IV	Right	2	2	1
	Left	2	2	

Table 3. Relation between Delano's optic nerve canal types and the presence of canal bony dehiscence

Type	Total	Bony dehiscence of optic nerves		P-value
		(+)	(-)	
I	155 (77.5%)	5 (3.2%)	150 (96.8%)	0.371
II	30 (15%)	2 (6.6%)	28 (93.4%)	0.718
III	7 (3.5%)	4 (57.1%)	3 (42.9%)	0.001
IV	8 (4%)	6 (75%)	2 (25%)	<0.001
Total	200 (100%)	17 (8.5%)	183 (91.5%)	

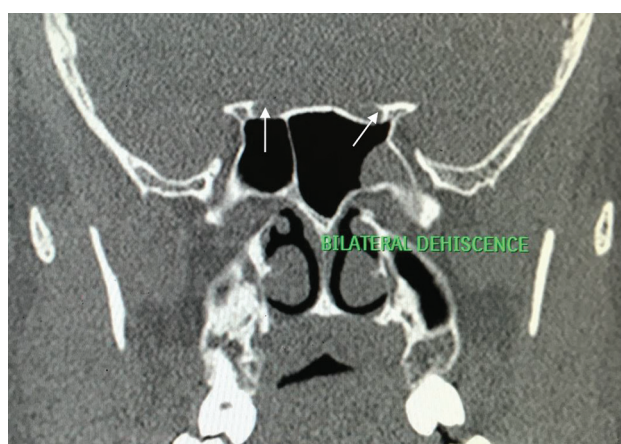


Fig. 5 Coronal CT image of a 33-year-old male showing bilateral bony dehiscence (white arrows).

Table 4. Relation between Delano's optic nerve canal type and pneumatization of the anterior clinoid process

Type	PACP		Total	P-value
	(+)	(-)		
I	0	155 (100%)	155 (100%)	0.771
II	2 (6.7%)	28 (93.3%)	30 (100%)	0.718
III	2 (28.5%)	5 (71.5%)	7 (100%)	0.04
IV	5 (62.5%)	3 (37.5%)	8 (100%)	0.001
Total	9 (4.5%)	191 (95.5%)	200 (100%)	

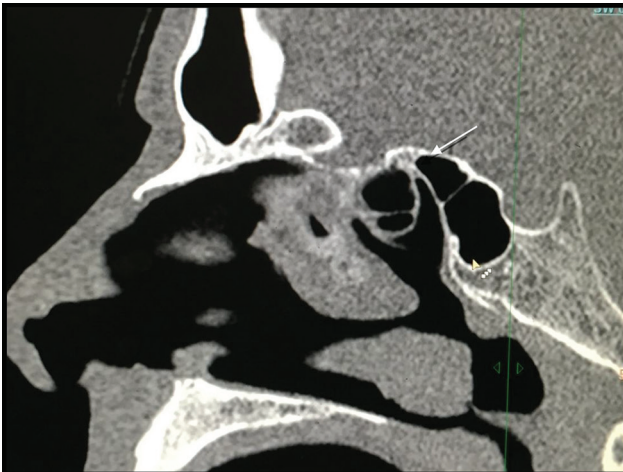


Fig. 6 Coronal CT image of a 46-year-old male showing pneumatization of the anterior clinoid processes (white arrow).

Table 5. Relation between Delano's optic nerve canal type and pneumatization of the posterior clinoid process

Type	PPCP		Total	P-value
	(+)	(-)		
I	0	155 (100%)	155 (100%)	0.999
II	0	30 (100%)	30 (100%)	0.998
III	2 (28.5%)	5 (71.5%)	7 (100%)	0.046
IV	2 (25%)	6 (75%)	8 (100%)	0.007
Total	4 (2%)	196 (98%)	200 (100%)	

Discussion

The analysis of the optic canals in relation to the sphenoid and posterior ethmoid sinuses in our sample of 100 Iraqi patients (200 canals) of middle Euphrates territory was as follows:

Prevalence of Delano's types

Overall, type I was the most commonly encountered relationship (77.5%), followed by type II with nearly equal prevalence of types III and IV. Up to our best knowledge, we found only three published studies conducted in neighboring and Arabic countries.¹⁵⁻¹⁷ Compared to Turkish study,¹⁵ type I was higher (77.5% versus 64%) while types II-IV were lower in our study. This difference between our patients and those populations is related to the ethnic variation as seen by Badia et al study.¹³ Although larger sample and wide multicentric anatomical surveys within different territories of Iraq may be more accurate, our current results alert Iraqi surgeons to be aware of this anatomical difference and not to rely on what is published in the anatomical textbooks or foreign literatures, to avoid serious damage to the optic nerve.

Delano's types and age

Although all types were generally more common in younger age groups, this was not statistically significant which has probably occurred because the majority of the examined patients with chronic rhinosinusitis was of young age group.

No statistically significant gender difference regarding types of optic nerve canals was seen in our patients and we could not compare this with other studies as they did not mention the gender distribution of Delano's types.

One of the important anatomical features that should be evaluated when interpreting a sinus CT scan is the optic canal bony dehiscence because this renders optic nerve more vulnerable to injury during surgical intervention. The Turkish study by Spaci et al¹⁵ found that bony dehiscence was more common in types II and III, while in our study, it was more common and statistically significant in types III (57.1%) and IV (75%). Therefore, bony dehiscence should be carefully looked for when optic nerve canal found to be in III or IV configuration, because the higher the type of Delano's, the higher the prevalence of bony dehiscence is.

The 4.5% prevalence of PACP (9 out of 200 optic nerve canals) was lesser than that in Turkey (22 cases, 11%),¹⁵ Libyans (46, 15.3%)¹⁶ and Sudan (28, 13.9%).¹⁷

Furthermore, because PACP was highest in types III and IV, radiologists can use them as indirect indicator of a higher Delano's type, hence a higher vulnerability of the optic nerve to surgical damage.

Similarly, because all four cases of PPCP were seen in types III (28.5%) and IV (25%) and no PPCP was seen in other types with statistically significant difference, PPCP (in addition to the PACP) could also be a warning sign for the presence of a serious optic nerve canal course. None of the other published studies included PPCP in their evaluations.

Limitations

Although the sample size of this study was according to the standardized statistical equation, we think that for our results to be generalizable, a larger sample from different regions of Iraq are required. Apart from few locations, there are no much published studies about the Delano's pattern of the optic canal in nearby counties to thoroughly compare our results with.

In conclusion, Delano's type I was the most common optic nerve canal course with no statistically significant age or gender difference. We think that to minimize complications and avoid risk of serious damage to the optic nerve, it is essential for Iraqi radiologists and ENT surgeons to have proper knowledge of this anatomical relationship and awareness of the current results regarding the slight anatomical difference between Iraqi and non-Iraqi populations.

Because optic canal bony wall dehiscence was more frequent in Delano's types III and IV, the study recommends that the radiologists should meticulously look for the dehiscence when a higher Delano's type is detected during pre-operative CT scan evaluation of PNS. Furthermore, presence of PACP and PPCP may alert for the presence of a serious optic nerve canal course.

Conflict of Interest

Authors wish to declare that there is no conflict of interest, including specific financial interests and relationships and affiliations relevant to the subject of the manuscript, exist with this study. ■

References

1. Rice DH, Schaefer SD. Anatomy of the Paranasal Sinuses. In: Rice DH, Schaefer SD. *Endoscopic Paranasal Sinus Surgery*. Lippincott Williams & Wilkins, 3rd ed., 2004.
2. Van Cauwenberge P, Sys L, De Belder T, Watelet JB. Anatomy and physiology of the nose and the paranasal sinuses. *Immunol Allergy Clin North Am*. 2004;24:1–17.
3. Sethi DS, Stanley RE, Pillay PK. Endoscopic anatomy of the sphenoid sinus and sella turcica. *J Laryngol Otol*. 1995;109:951–955.
4. Bolger WE. Anatomy of the Paranasal Sinuses. In: Kennedy DW, Bolger WE, Zinreich J. *Diseases of the sinuses, Diagnosis and Management*. B.C. Decker, 2001.
5. Stammberger HR, Kennedy DW. Anatomic Terminology Group. Paranasal sinuses: anatomic terminology and nomenclature. *Ann Otol Rhinol Laryngol Suppl*. 1995;167:7–16.
6. Kantarci M, Karasen RM, Alper F, Onbas O, Okur A, Karaman A. Remarkable anatomic variations in paranasal sinus region and their clinical importance. *Eur J Radiol*. 2004;50:296–302.
7. Stammberger H, Kopp W. *Functional Endoscopic Sinus Surgery: the Messerklinger Technique*. Philadelphia, B.C. Decker, 1991, p. 283.
8. Backous DD, Esquivel CR. *Skull Base Medical and Surgical Issues Commonly Encountered in the Practice of Otolaryngology*, Vol. 38, 2005, pp. 13–14.
9. Sellari-Franceschini S, Berrettini S, Santoro A, Nardi M, Mazzeo S, Bartalena L, et al. Orbital decompression in Graves' ophthalmopathy by medial and lateral wall removal. *Otolaryngol Head Neck Surg*. 2005;133:185–189.
10. Fokkens W, Lund V, Mullol J. European position paper on rhinosinusitis and nasal polyps group. *Zhonghua Er Bi Yan Hou Tou Jing Wai Ke Za Zhi*. 2008;43:317–320.
11. Cumberworth VL, Sudderick RM, Mackay IS. Major complications of functional endoscopic sinus surgery. *Clin Otolaryngol Allied Sci*. 1994;19:248–253.
12. Zinreich SJ. Functional anatomy and computed tomography imaging of the paranasal sinuses. *Am J Med Sci*. 1998;316:2–12.
13. Badia L, Lund VJ, Wei W, Ho WK. Ethnic variation in sinonasal anatomy on CT-scanning. *Rhinology*. 2005;43:210–214.
14. DeLano MC, Fun FY, Zinreich SJ. Relationship of the optic nerve to the posterior paranasal sinuses: a CT anatomic study. *AJNR Am J Neuroradiol*. 1996;17:669–675.
15. Sapçı T, Derin E, Almaç S, Cumali R, Saydam B, Karavuş M. The relationship between the sphenoid and the posterior ethmoid sinuses and the optic nerves in Turkish patients. *Rhinology*. 2004;42:30–34.
16. Hewaidi G, Omami G. Anatomic variation of sphenoid sinus and related structures in Libyan population: CT scan study. *Libyan J Med*. 2008;3: 128–133.
17. Kajoak SA, Ayad CE, Najmeldeen M and Abdalla EA. Computerized Tomography morphometric analysis of the sphenoid sinus and related structures in Sudanese Population. *Glob Adv Res J Med Med Sci*. 2014;3:160–167.

This work is licensed under a Creative Commons Attribution-NonCommercial 3.0 Unported License which allows users to read, copy, distribute and make derivative works for non-commercial purposes from the material, as long as the author of the original work is cited properly.