

Effect of long-term administration of Atonik compound in female rabbits on hematological and pathological changes in important functional body organ

Adnan MJ,^a Mohamed Abed Razah,^b Ghusoon AK Al-Neamah,^c Hayder A.A. Al-Dulaimi,^c Rawaa Safaa^a

^aDepartment of pharmacology, college of veterinary medicine, Alqassim university, Iraq.

^bDepartment of pharmacology, college of pharmacy/Alqadisia university, Iraq.

^cDepartment of Pathology, college of veterinary medicine/Alqassim university, Iraq.

Correspondence to Adnan M.J. (email: adnan.mansour81@gmail.com).

(Submitted: 24 May 2016 – Revised version received – 11 June 2016 – Accepted: 13 July 2016 – Published online: 26 September 2016)

Objectives This study includes the investigation of stimulant plant growth compound Atonik's harmful effect in some important function of body organs of rabbits.

Methods Twelve female rabbits weighting 1.4–1.6 kg were obtained from animal house in the college of Veterinary Medicine and they were housed for 2 weeks before the beginning of study and all laboratory condition were taken into consideration. Animals were randomly divided into two main groups: Control group without treatment at all periods of study, Atonik group: each rabbit was orally received 0.1 mg/kg/three time weekly (TIDW) and study was persistent for eight weeks.

Results Our result reveals the disturbance of hematological parameters specially WBCS, RBCS, HB and lymphocyte. Moreover, histopathological section showing dilation of the central vein filled with fluid and granuloma beside it with vacuolation of hepatocyte. The kidney reveals coagulative necrosis of renal tubules with the distraction of glomerular tuft. Uterus of rabbits treated with 0.1 mg/kg bw atonik for 8 weeks showing necrosis of unrein glands. Ovary showed an increase in the numbers of atretic follicles. Our result concluded that atonik has a very harmful effect for reproduction, liver and kidney.

Conclusion Use of atonik plant growth hormones reveal very harmful effect in reproductive and functional organ of rabbits, In addition to that, limited use of atonik hastens plant growth specially fruits such as figs, which is characteristic with low maturity period that should be used with safety period at least 2 weeks.

Keyword Atonik, ovary, uterus, nitro phenol

Introduction

Atonik is a synthetic biostimulant consists of three phenolic compounds: sodium para-nitrophenolate PNP (0.3%), sodium ortho-nitrophenolate ONP (0.2%) and sodium 5nitroguaiacolate 5NG (0.1%), and water. Atonik is used as a stimulant for plant growth and development, particularly generative.^{1,2} The fresh weight and dry matter, and production are increased so that there is a higher leaf area, with rich chlorophyll content, supported by an improvement of chlorophyll *a* fluorescence parameters. The application of atonik plays a stimulative role under optimal conditions and protective against spring frost, drought, and noble metal stresses.³ The positive effect of atonik is more preferable when plants grow under stress conditions. The mechanism of action through increased nutrient uptake by increased cytoplasmic streaming and prolongation of auxin activity via inhibiting the indolylacetic acid and abscissic acid increases the nitrate reductase activity.⁴ Although plant regulator is important, some residues of agent may not be excreted from plant specially if given for fruit that may lead to toxicological effect on animal and human body tissue. When atonik was taken orally, it is well absorbed by gastrointestinal tract and reaches to blood circulation via portal vein within 30 minutes and high level in the blood of atonik after 2 hours of administration. It is widely distributed all over the body with the highest concentrations in carcass, kidneys, liver and the intestinal tract, and also excreted through urine. Sodium orthonitrophenolate (OPP) is also used as fungicides after harvest treatment of citrus fruits and as disinfectants and preservatives [FAO]. Moreover, it is widely used in agriculture, and as disinfectants in food utensil.⁵ It is also reported that rats and mice treated with multi dose of organ phosphorus poisoning (OPP) (0,25,10,25 mg/kg bw) reveal diminish in fetal body weight, high incidences

in delayed skeletal ossification and percent post-implantation loss (12.2; 16.7; 19.2; 18.3, respectively). In addition, fetal mice treated with SOPP showed malformation (mice: cleft plate; rabbits: resorptions). *P*-Nitrophenol (PNP) is a major metabolite of some organophosphorus such as parathion and methyl parathion.⁶

In fact, PNP is an intermediate chemical agent widely used in the manufacture of some drugs, fungicides, dyes, and is considered as organic pollutant.⁷ High abuse of organ phosphorus leads to bioaccumulation of PNP.⁸ Therefore, the OP insecticide abuse increases humans, livestock, and wild animal exposure to PNP toxicity, which lead to severe environmental pollution and increase health problem.^{8,9} PNP has an adverse effect on endocrine system in male due to the inhibition of androgen and estrogenic activity that can be recorded *in vitro* and *in vivo*. Moreover 3-methyl-4-nitrophenol and 4-nitro-3-phenylphenol at dose 100 mg/kg PNM and 0.1 and 1.0 mg/kg, respectively to ovariectomized immature female rats *subcutaneously for 2 days showed significant increases in uterine weight and estrogenic activity*. The purpose of the present study was to detect the effects of orally administrated atonik to rabbits on the haematological and histological importance of internal organs due to widely abused the compound for hastening plant growth specially Fruits such as Figs whose maturity period is very short than consumed by human.

Materials and Methods

Animal Study

Twelve female rabbits of weighting between 1.4 and 1.6 kg were obtained from animal house in college of Veterinary

Medicine. They were housed for 2 weeks before the beginning of the study. All laboratory conditions were considered. All animals were randomly divided into two main groups:

1. Control group: Without treatment at all throughout the period of study.
2. Atonik group: Each rabbit was orally received 0.1 mg/kg/three time weekly (TIDW) for eight weeks. At the end of the experiment, blood sample was obtained via ear technique and xylazine–ketamine anesthesia were used for hematological parameters with scarified animal for taking specimen (liver, kidney, ovary) were fixed immediately in 10% formalin.

Atonik solution was purchased from an agricultural officer in AL-Qassim city, from Japan company origin.

Results

The result showed an increase of WBCS, RBCS, lymphocyte and granulocyte of atonik treated group (Table 1).

Table 1. Effect of atonik on some blood parameters of local rabbits

Traits	First group (Control)	Second group (Atonik)	Mean ± SE (mean, SE standard error)
No. of rabbits	6	6	6
WBC ($\times 10^3$ cells/ml ³): *	6.3250 ± 0.31 B	7.9000 ± 0.43 A	7.1125 ± 0.37
RBC ($\times 10^6$ cells/ml ³): NS	4.3650 ± 0.53 A	5.0525 ± 0.32 A	4.7087 ± 0.42
Hb (gm): NS	8.77 ± 0.31 A	6.80 ± 1.70 A	7.78 ± 1.00
PCV (%): **	23.50 ± 1.44 B	28.47 ± 0.62 A	25.98 ± 1.03
Lymphocytes (%): **	37.26 ± 2.81 B	54.57 ± 4.08 A	45.91 ± 3.44
Monocyte (%): NS	7.52 ± 0.39 A	8.90 ± 1.22 A	8.21 ± 0.80
Granulocytes (%): *	55.07 ± 1.54 A	47.87 ± 2.65 B	51.47 ± 2.09

The traits that carried different letters horizontally indicates significant differences at probability 0.05 or 0.01. NS: non-significant; *significant differences at 0.05; **high significant differences at 0.01.

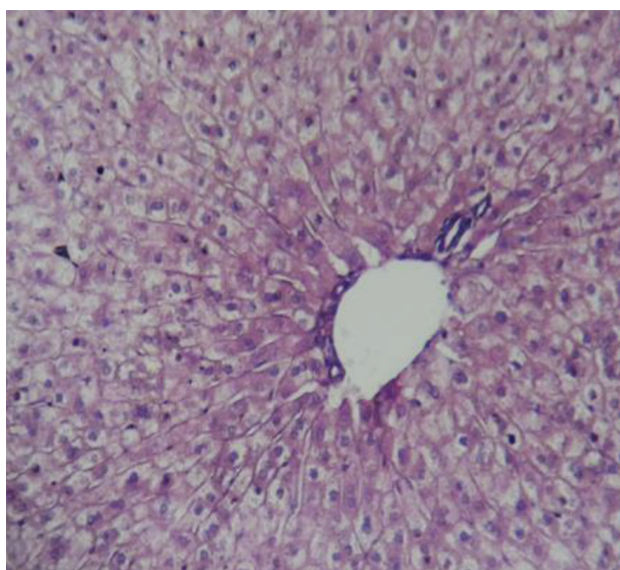


Fig. A1 Histopathological section of control groups showing normal histological structures.

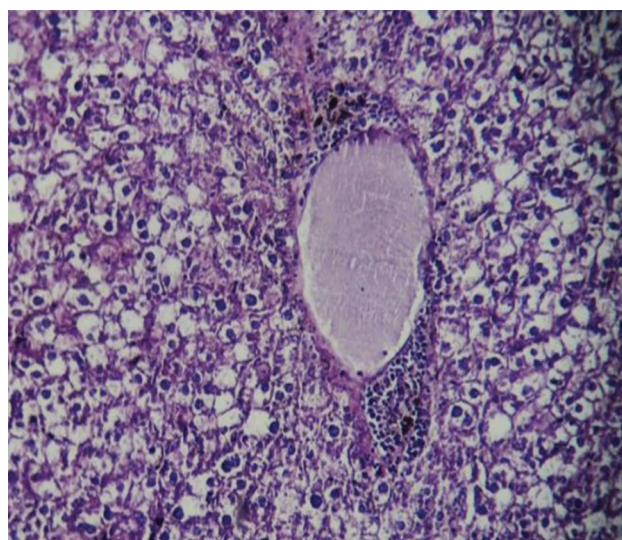


Fig. A2 Histopathological section of liver of rabbits treated with 0.1 mg/kg bw of atonik for 8 weeks showing dilation of the central vein and filled with fluid and granuloma beside it, with vacuolation of hypatocyte.

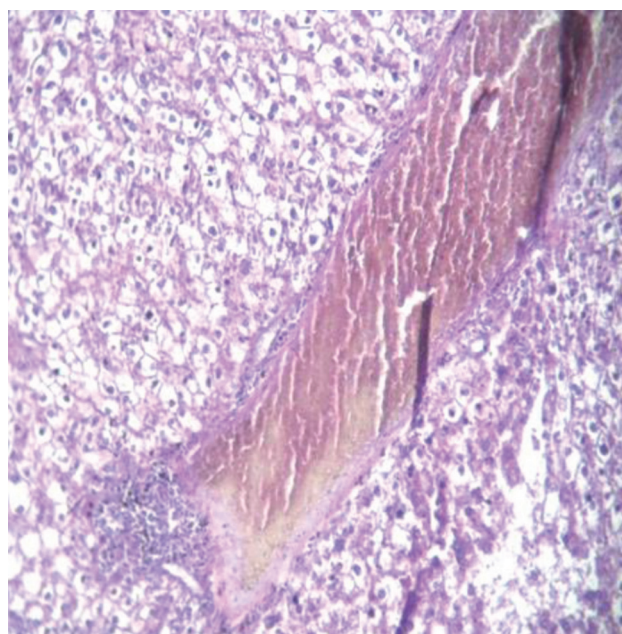


Fig. A3 Histopathological section of liver of rabbits treated with 0.1 mg/kg bw atonik for 8 weeks showing dilation and congestion of the central vein, with inflammatory cell infiltration.

Discussion

In the present study, the experimental groups showed a disorganized hepatic architecture with marked affection of the hepatocytes due to periportal fibrosis. Liver fibrosis represents the final common pathway of almost all types of chronic liver diseases characterized by excessive connective tissue deposition in extracellular matrix (ECM). ROS can activate fibrogenic gene expression and transforming growth factor (TGF- β 1) signaling pathway, which is known to play a major role in the activation of hepatic stellate cells (HSCs) in liver fibrosis.¹⁰ The result showed that the increase of WBCS, RBCS, lymphocyte and granulocyte of atonik-treated group that may

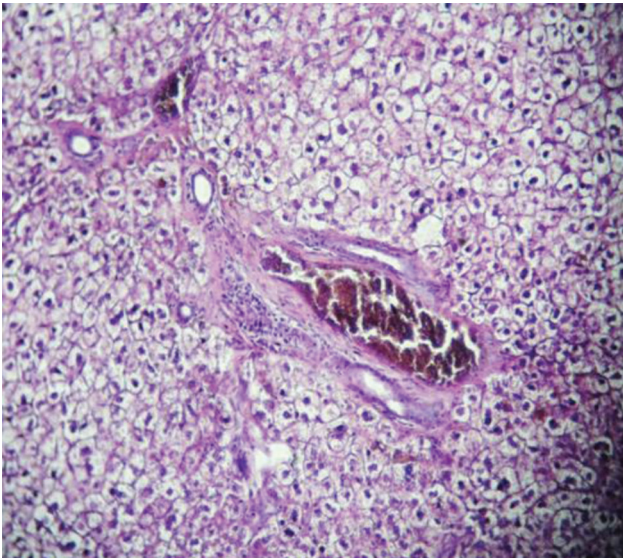


Fig. A4 Histopathological section of liver of rabbits treated with 0.1 mg/kg bw atonik for 8 weeks showing congestion and thickening of portal area with inflammatory cell infiltration.

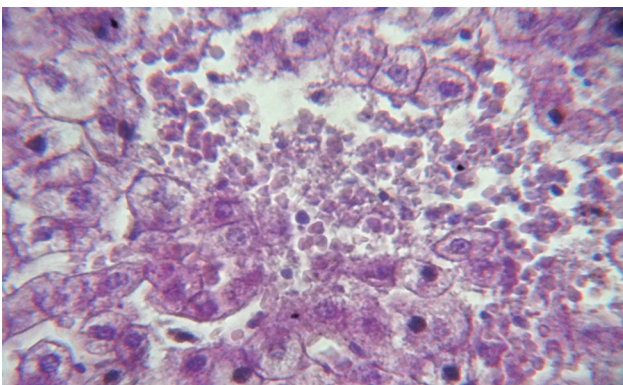


Fig. A5 Histopathological section of liver of rabbits treated with 2 mg/kg bw 0.1 mg/kg bw atonik for 8 weeks showing distraction of hepatic tissue with hemorrhage.

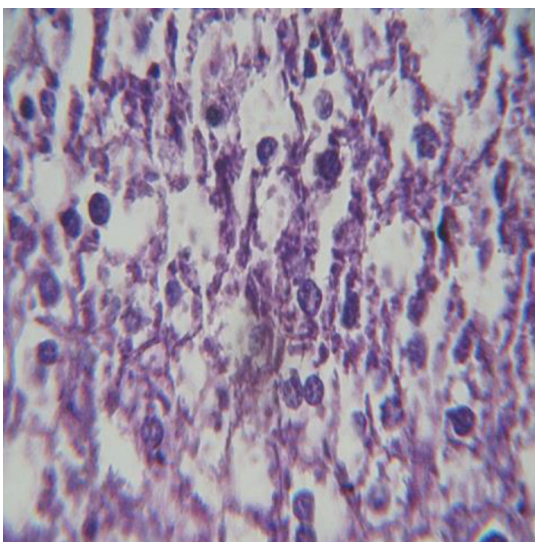


Fig. A6 Histopathological section of liver of rabbits treated with 0.1 mg/kg bw atonik for 8 weeks showing necrosis of hepatic tissue.

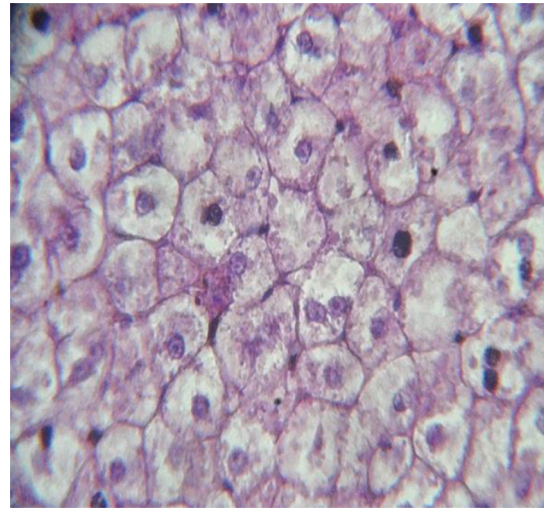


Fig. A7 Histopathological section of liver of rabbits treated with 0.1 mg/kg bw atonik for 8 weeks showing hydropic degeneration of hepatocyte.

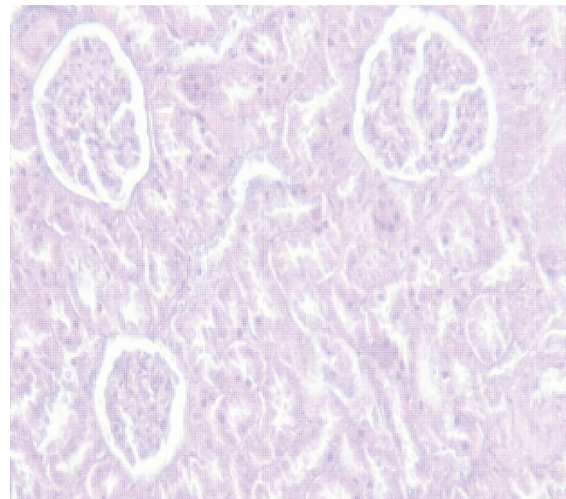


Fig. B1 Histopathological section of kidney of control groups showing normal histological structure.

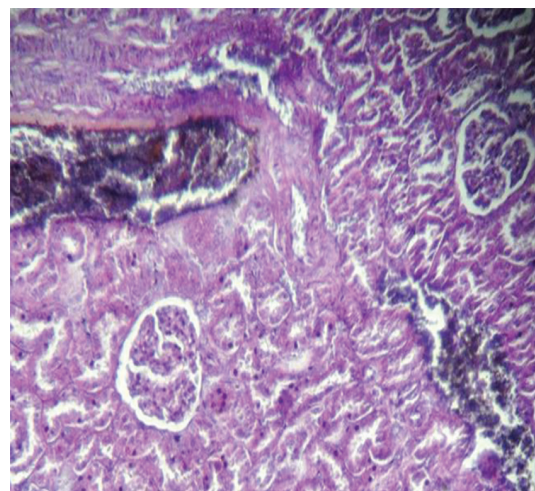


Fig. B2 Histopathological section of kidney of rabbits treated with 0.1 mg/kg bw atonik for 8 weeks showing dilation and congestion of the renal artery with hemorrhage.

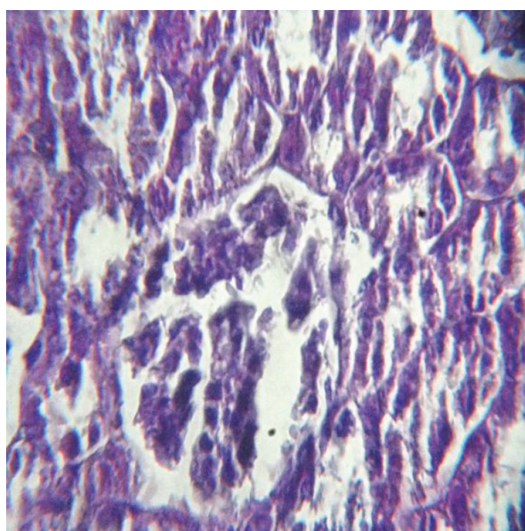


Fig. B3 Histopathological section of kidney of rabbits treated with 0.1 mg/kg bw atonik for 8 weeks showing coagulative necrosis of renal tubules with distraction of glomerular tuft.

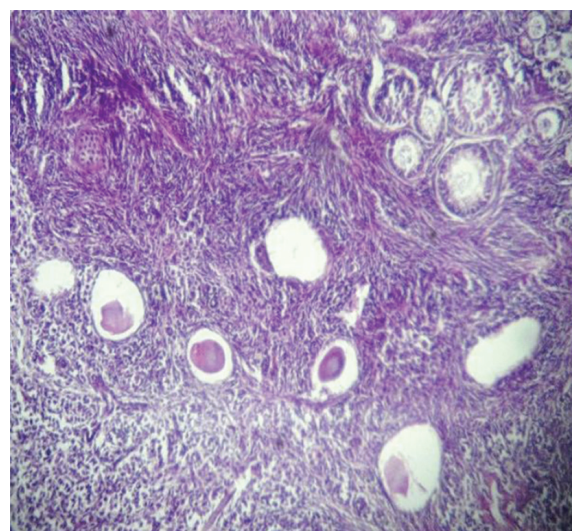


Fig. C3 Histopathological section of ovary of rabbits treated with 2 mg/kg bw sodium nitrophenolate for 8 weeks increase in the numbers of atretic follicles.

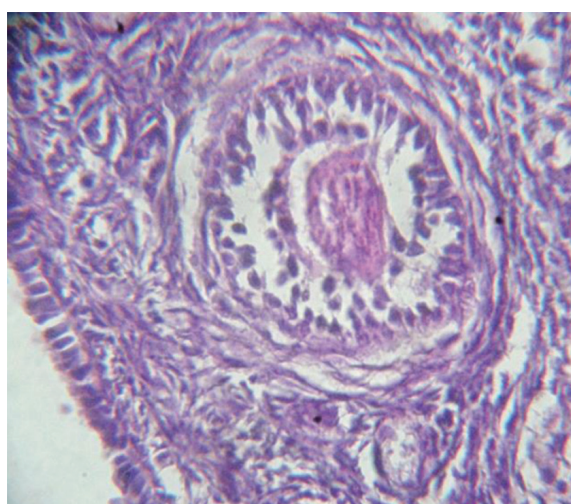


Fig. C1 Histopathological section of ovary of control groups showing normal histological structure.

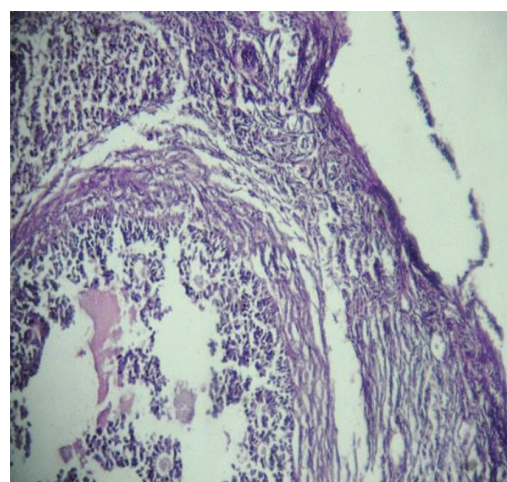


Fig. C4 Histopathological section of ovary of rabbits treated with 2 mg/kg bw sodium nitrophenolate for 8 weeks showing sloughing of epithelial cells lining, with degranulation of granulosa cells.

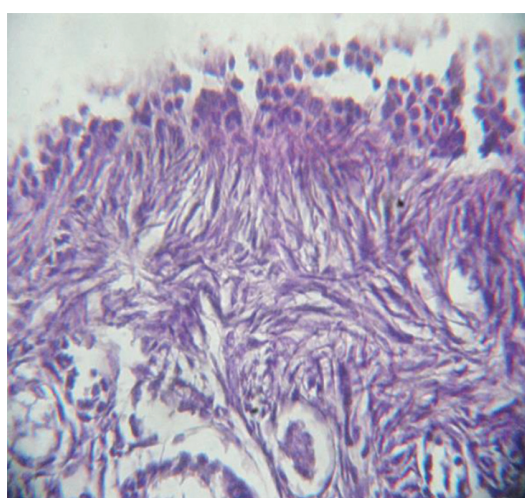


Fig. C2 Histopathological section of ovary of rabbits treated with 0.1 mg/kg bw atonik for 8 weeks showing squamous metaplasia of epithelial cells lining the ovary.

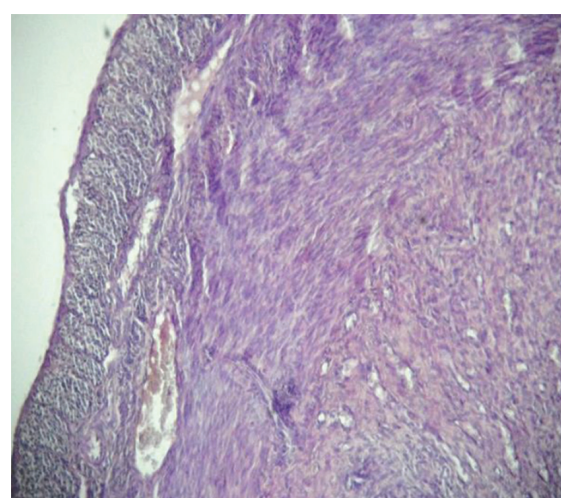


Fig. D1 Histopathological section of uterus of rabbits treated with 0.1 mg/kg bw atonik for 8 weeks showing congestion of uterine blood vessels.

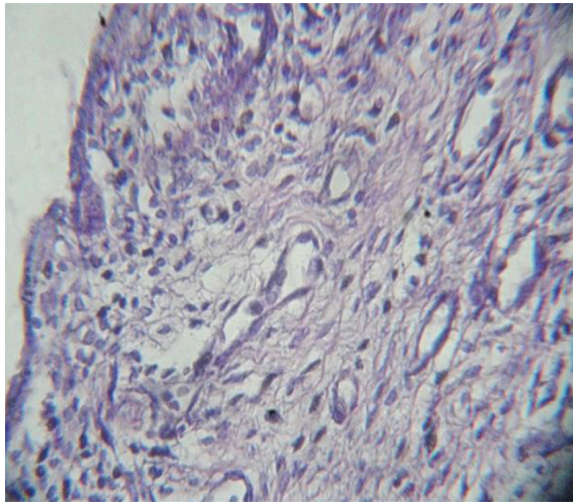


Fig. D2 **Histopathological section of uterus of rabbits treated with 0.1 mg/kg bw atonik for 8 weeks showing necrosis of unrein glands.**

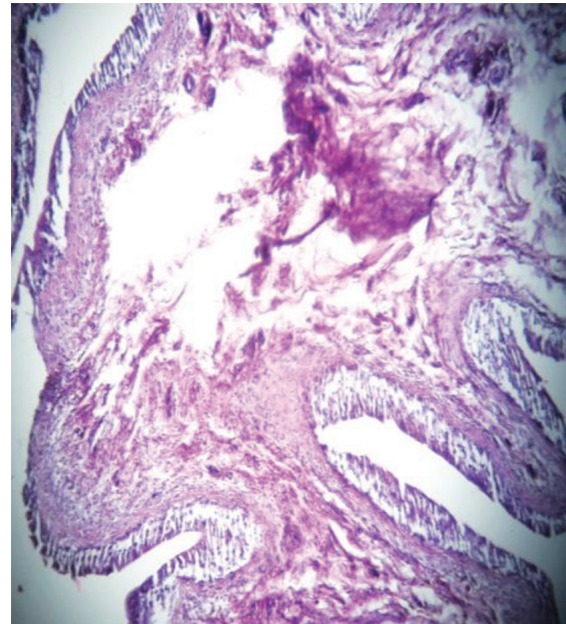


Fig. E2 **Histopathological section of oviduct of rabbits treated with 0.1 mg/kg bw atonik for 8 weeks showing severe distraction of lamina propria with sloughing of epithelial cell lining.**

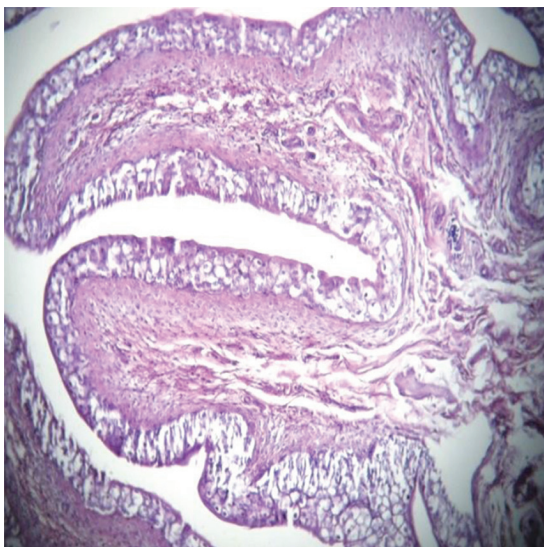


Fig. E1 **Histopathological section of oviduct for control groups showing normal histological structure.**

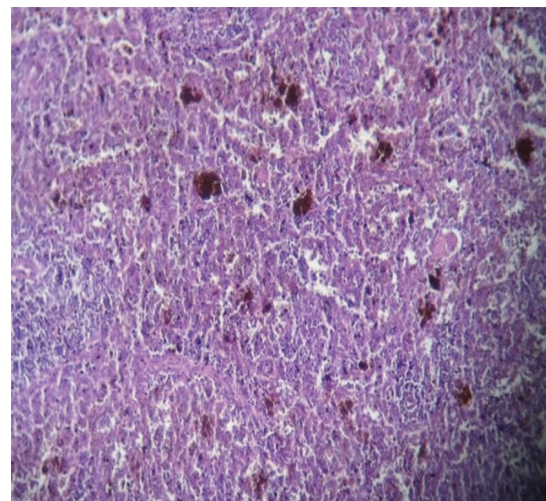


Fig. F1 **Histopathological section of spleen of rabbits treated with 0.1 mg/kg bw atonik for 8 weeks showing depletion in lymphoid follicles and hemosiderosis.**

be due to the activity of agent as androgenic action induces erythrocytosis by stimulating erythropoietin production. The results show that the animals exposed to sodium nitrophenolate exhibited extensive area of coagulative necrosis with severe dilation and congestion of blood vessels of liver, kidneys and uteri. Necrosis may result from the accumulation of sodium nitrophenolates in the mitochondria and lysosomes progressive hepatocyte organelles damage, cellular degeneration and necrosis.¹¹ In addition, the similar results, such as hypoxia in the perivenular region with an increase in hepatic oxygen demand without an appropriate in hepatic blood flow were also obtained in previous research.¹²⁻¹⁵ Previous study indicated that necrotic lesions can be a cause of oxidative stress induced by sodium nitrophenolates.¹⁶ This result agrees with some studies carried by previous research¹⁷ whom reported the congestion in liver, kidneys and ulcers of the stomach in high doses in rats. Others noted many effects including decreased in body weight gain, differences in organ weights, and focal fatty changes of livers. These changes are

related to the kind of substrates that come to the reaction. Also its localization in the hematological examination, clinical chemistry and histopathological examination of the major organ and tissues did not give any indication of a substance-related toxic effected in comparison with the control. The recent study reported that quails were orally given (0.01, 0.1, 1) mg/kg bw of PNP for 75 days. Liver and plasma samples were collected at days 45 (45, 60, 75 day) The results of liver showed lymphocytic infiltration, congestion of blood vessels and degeneration of hepatocytes also positive increases in corticosterone levels were record. Moreover, after 60-days of *in vivo* exposure, the quills exhibited an overexpression in the liver CYP1A4, 1B1, AhR1, and HO-1. Furthermore, with 75 days, an overall down regulation of the tested genes was observed. *In vitro*, although a significant overexpression of

CYP1A4, 1B1, and HO-1 was observed, CYP1A5 was down regulated.⁸

The histopathological changes of spleen tissues showing depletion of lymphoid tissue and that can be related to the effect of the compound which causes depression in the immune system. Similar results were also obtained by other researchers^{17,18} whom reported that the administration of 4-nonylphenol to rats in doses of 125–375 mg/kg of body weight caused changes in the activity of the immunological system. The current study showed that sodium nitrophenolate toxicity leading to significant changes in both uteri and ovaries could lead to infertility however with regard reproductive toxicity testing.

The present study showed follicular atresia. This may be due to sodium nitrophenolates that disturbed the reproductive hormones. This result agreed with^{19–24} Whom reported that Phenols also affect the function of the hormonal system. Some phenols are capable of disturbing sexual hormone function, which may finally lead to sterility of animals and humans. In another experiment bisphenol A caused protein expressions in TM4 cells in mice, which play a key role in spermatogenesis. It was noted that the viability of cells decreased to 10 to 70% after exposure to doses of 50–250 µM/kg of body weight over 16 hours. Obtained results showed that bisphenol A may induce infertility in mice. In an oral study with rats, 2-nitrophenol induced developmental effects in the offspring only at doses that also produced maternal toxicity. The literature reported that 4-Nitro-3-phenylphenol possesses both androgenic and anti-androgenic effect,^{17,26} and the treatment with agent showed a decrease of FSH and LH secreted from the pituitary

cells without GnRH activation. Contrariwise, 10^{-5} – 10^{-7} M of agent for 1 day can increase hormones when the cells were stimulated with GnRH. On the other hand, leydig cell culture treated with (10^{-5} – 10^{-9} M) of agent appear significantly increased testosterone, in the presence or absence hCG. Immature female rats administrated subcutaneously with 10, or 100 mg/kg PNP daily for one week, reveal significant increases in uterine weight.⁹ Our results therefore suggest that atonik can lead to the accumulation of main compound specially PNP in water, and soil, so that could have serious harmful effects on wildlife and human health. Histopathological section of kidney of rabbits treated with 0.1 mg/kg bw atonik for 8 weeks showing dilation and congestion of the renal artery with hemorrhage accompanied with coagulative necrosis of renal tubules with the distraction of glomerular tuft. Dilation of the urinary space of the renal corpuscles in atonik-treated rabbits because of basement. Membrane alterations and proximal convoluted tubule epithelial destruction decrease the physiological functional leading to the alteration of glomerular filtration and the accumulation of fluid in the urinary space. Our study was concorded with other researches,^{15,25} and demonstrated high percent of creatinine, blood urea nitrogen, alkaline phosphatase which consider waste products of protein metabolism that excreted by the kidney and give indicators of kidney destruction as in the other study conducted on rat reveal that nitrophenol compound cause deformity in the shape of mitochondria with dense deposits in the basement membranes of the glomeruli was noted in electron microscope.^{15,28}

References

- Cerny I, Pacuta V, Kovar M. Yield and quality of chicory (*Cichorium intybus* L.) in dependence on variety and foliar application of Atonik and Polybor 150. *J Central Eur Agric*. 2008;9:425–430.
- Calvo P, Nelson L, Kloepper JW. Agricultural uses of plant biostimulants. *Plant soil*. 2014;383:3–41.
- Djanaguiraman M, Sheeba JA, Devi DD, Bangarusamy U. Cotton leaf senescence can be delayed by nitrophenolate spray through enhanced antioxidant defence system. *J Agron Crop Sci*. 2009;195: 213–224.
- Przybysz A, Gawrońska H, Gajc-Wolska J. Biological mode of action of a nitrophenolates-based biostimulant: case study. *Front Plant Sci*. 2014;5:713.
- Kwok Eric SC, Marilyn Silva. Re-evaluation of developmental and reproductive toxicity of ortho-phenylphenol (OPP) and sodium ortho-phenylphenate (SOPP). *Cell Dev Biol*. 2013;2:3.
- Abu-Qare AW, Abdel-Rahman AA, Kishk AM, Abou-Donia MB. Placental transfer and pharmacokinetics of a single dermal dose of [¹⁴C] methyl parathion in rats. *Toxicol Sci*. 2000;53:5–12.
- Zhang G, Gao Y, Zhang Y, Guo Y. Fe₂O₃-pillared rectorite as an efficient and stable Fenton-like heterogeneous catalase for photodegradation of organic contaminants. *Environ Sci Technol*. 44:6384–6389.
- Ahmed E, Nagaoka K, Fayez M, Abdel-nDaim MM, Samir H, Watanabe G. Suppressive effects of long-term exposure to P-nitrophenol on gonadal development, hormonal profile with disruption of tissue integrity, and activation of caspase-3 in male Japanese quail (*Coturnix japonica*). *Environ Sci Pollut Res Int*. 2015;22:10930–10942.
- Li C, Taneda S, Suzuki A, Furuta C, Watanabe G, Taya K. Estrogenic and anti-androgenic activities of 4-nitrophenol in diesel exhaust particles. *Toxicol Appl Pharmacol*. 2006;217:1–6.
- Bartosz G. Reactive oxygen species: destroyers or messengers *Biochem Pharmacol*. 2008;77(8):1303–1315.
- Abu-Qare AW, Abdel-Rahman AA, Ahmad H, Kishk AM, Abou-Donia MB. Absorption, distribution, metabolism and excretion of daily oral doses of [¹⁴C] methyl parathion in hens. *Toxicol Lett*. 2001;125:1–10.
- Hansel WM, Gonzalo JD, Sandra MC. Enzymatic activity in turkey, duck, quail and chicken liver microsomes against four human cytochrome P450 prototypesubstrates and aflatoxin B. *Xenobiotics*. 2011;1:1.
- EFSA Scientific Report Conclusion on the peer review of sodium 5-nitroguaiacolate, sodium o-nitrophenolate and sodium p-nitrophenolate. European food safety authority, 2008;191:1–130.
- Tsai Ch -H, Li NP-H, Waidyanatha S, Rappapor TM. Characterization of metabolic activation of pentachlorophenol to quinones and semiquinones in rodent liver. *Chem Biol. Interact*. 2001;134:55.
- Tootian Z, Monfared AL, Fazelipour S, Shyban MT, Rouhollah F, Sasani F, et al. Biochemical and structural changes of the kidney in mice exposed to phenol. *Turk J Med Sci*. 2012;42(4):695–703.
- Sikka SC. Relative impact of oxidative stress on male reproductive function. *Curr Med Chem*. 2001;8:851–862.
- Boehnecke A, Koennecker I, Mangelsdorf I, Wibbertmann A. Fraunho Mononitrophenols. World Health Organization 2000:1–37.
- Michałowicz J, Duda W. Phenols – Sources and Toxicity. *Polish J Environ Stud*. 2007;16:347–362.
- Koerdel W, Kuhnen-Clausen D, Fabig W, Otto F. Evaluation of test guidelines for environmental chemicals. Schmallenberg Fraunhofer Institute for Environmental Chemistry and Ecotoxicology.
- Yoshida R, Oikawa S, Ogawa Y, Miyakoshi Y, Ooida M, Asanuma K, et al. Mutagenicity of paminophenol in *E. coli* WP2uvrA/pKM 101 and its relevance to oxidative DNA damage. *Mutat Res*. 1998;415: 139–50.
- Arkadiusz Przybysz, Helena Gawrońska, Janina Gajc-Wolska Biological mode of action of a nitrophenolates-based biostimulant: case study. *Front Plant Sci*. 2014;5:713.
- Zhang Y, Piao Y, Li Y, Song M, Tang P, Li C. 4-Nitrophenol induces Leydig cells hyperplasia, which may contribute to the differential modulation of the androgen receptor and estrogen receptor- α and - β and expression in male rat testes. *Toxicol Lett*. 2013;223:228–35.
- Eric SC Kwok, Marilyn Silva. Re-evaluation of developmental and reproductive toxicity of ortho- phenylphenol (OPP) and sodium ortho-phenylphenate (SOPP) *Cell Dev Biol*. 2013;2:3–74.

24. Jung J, Ishi DA K, Nishih Ara T. Anti-estrogenic activity of fifty chemicals evaluated by *in vitro* assays. *Life Sci.* 2004;74:3065.
25. Dasmahapatra AK, Trewin AL, Hutz RJ. Estrous cycle- regulated expression of CYP1B1 mRNA in the rat ovary. *Comp Biochem Physiol B Biochem Mol Biol.* 2002;133: 127–134.
26. Trisomboon J, Li C, Suzuki A, Watanabe G, Taya K. 4-Nitro-3-phenylphenol has both androgenic and anti-androgenic-like effects in rats. *J Reprod Dev.* 2015; 61(2):134–137.
27. Nakazawa T, Kasahara K, Ikezaki S, Yamaguchi Y, Edamoto H, Nishimura N, et al. Renal tubular cyst formation in newborn rats treated with p-cumylphenol. *J Toxicol Pathol.* 2009;22:125–131.